

### Perianal Disease with Gross Rectal Lesion

#### *Functionally Intact Sphincter and Perineum*

Fecal diversion is required in these patients. During diversion the intraabdominal component of the disease is excised and local fistulas appropriately treated. Healing occurs within three to four months, at which time intestinal continuity may be reestablished. Failure of the perineal wound to heal is a possible indication for proctectomy.

#### *Functionally Destroyed Sphincter or Perineum*

These patients require proctectomy. The proximal extent of the resection depends on the involvement of the colon, but most patients require total proctocolectomy. If there is notable perineal sepsis, the proctectomy may be done as a second stage to avoid contamination. Healing of the perineal defect may call for skin or composite grafts.

\* \* \*

Familiarity with the collected data concerning Crohn's colitis, coupled with an understanding of the natural course of the disease, allows the surgeon to choose an appropriate operation to alleviate the patient's symptoms and avoid the disabling complications classically associated with the disease.

#### REFERENCES

1. Lockhart-Mummery HE, Morson BC. Crohn's disease (regional enteritis) of the large intestine and its distinction from ulcerative colitis. *Gut*. 1960; 1:87-105.
2. Yardley JH, Donowitz M. Colo-rectal biopsy in inflammatory bowel disease. In: Yardley JH, Morson BC, Abell MR, eds. *The gastrointestinal tract*. Baltimore: Williams & Wilkins, 1977:50-94.
3. Enker WE, Block GE. The operative treatment of Crohn's disease complicated by fistulae: a personal consecutive series. *Arch Surg*. 1969; 98:493-9.
4. Baker WNW. Ileo-rectal anastomosis for Crohn's disease of the colon. *Gut*. 1971; 12:427-31.
5. Turnbull RB Jr. The surgical approach to the treatment of inflammatory bowel disease; a personal view of techniques and prognosis. In: Kirsner JB, Shorter RG, eds. *Inflammatory bowel disease*. Philadelphia: Lea & Febiger, 1975:338-84.
6. Goligher JC. The outcome of excisional operations for primary and recurrent Crohn's disease of the large intestine. *Surg Gynecol Obstet*. 1979; 148:1-8.
7. Fawaz KA, Glotzer GJ, Goldman H, Dickersin GR, Gross W, Patterson JF. Ulcerative colitis and Crohn's disease of the colon — a comparison of the long term postoperative course. *Gastroenterology*. 1976; 71:372-8.
8. Bergman L, Krause U. Postoperative treatment with corticosteroids and salazosulphapyridine (Salazopyrin®) after radical resection for Crohn's disease. *Scand J Gastroenterol*. 1976; 11:651-6.
9. Weedon DD, Shorter RG, Ilstrup DM, Huizenga KA, Taylor WF. Crohn's disease and cancer. *N Engl J Med*. 1973; 289:1099-103.
10. Farmer RG, Hawk WA, Turnbull RB Jr. Indications for surgery in Crohn's disease: analysis of 500 cases. *Gastroenterology*. 1976; 71:245-50.
11. Block GE. Empiric caval interruption in operations for inflammatory bowel disease. *Curr Surg*. 1978; 35:297-8.
12. Hudspeth AS. Radical surgical debridement in the treatment of advanced generalized bacterial peritonitis. *Arch Surg*. 1975; 110:1233-6.
13. Bull DM, Peppercorn MA, Glotzer DJ, Joffe N, Goldman H, Silen W. Crohn's disease of the colon. *Gastroenterology*. 1979; 76:607-21.
14. Jalan KN, Smith AN, Ruckley CV, Falconer CWA, Small WP, Prescott RJ. Perineal wound healing in ulcerative colitis. *Br J Surg*. 1969; 56:749-75.
15. Silen W, Glotzer DJ. The prevention and treatment of the persistent perineal sinus. *Surgery*. 1974; 75:535-42.
16. Kock NG, Darle N, Hultén L, Kewenter J, Myrvold H, Philipson B. Ileostomy. *Curr Probl Surg*. 1977; 14(8):1-52.

### HIGH-ALTITUDE PULMONARY EDEMA IN PERSONS WITHOUT THE RIGHT PULMONARY ARTERY

PETER H. HACKETT, M.D.,  
C. EDWARD CREAGH, M.D.,  
ROBERT F. GROVER, M.D.,  
BENJAMIN HONIGMAN, M.D.,  
CHARLES S. HOUSTON, M.D.,  
JOHN T. REEVES, M.D.,  
ARIS M. SOPHOCLES, M.D.,

AND MECHTELD VAN HARDENBROEK, M.D.

**H**IGH-ALTITUDE pulmonary edema is an unusual and puzzling illness.<sup>1,2</sup> We have seen four patients without a right pulmonary artery, all of whom had high-altitude pulmonary edema at moderate altitudes (2000 to 3000 m) in Colorado. Both of these conditions are so uncommon that their association by chance is highly unlikely. The implications of this association were recognized by Dr. Houston when the first of our four cases was called to his attention by another member of the group. In each of the four patients edema developed in the left lung, which received the entire right ventricular output. This occurrence suggests that the hemodynamic alterations of high pressure and flow in the pulmonary artery are important in the pathogenesis of high-altitude pulmonary edema. Persons lacking the right pulmonary artery appear to have a high risk of life-threatening lung edema at even modest altitude, and, conversely, such a condition should be suspected when severe pulmonary edema occurs at less than 3000 m.

#### CASE REPORTS

##### Patient 1

A 26-year-old man from Green Bay, Wisc. arrived in Winter Park, Colo. (altitude, 2750 m), on the morning of January 26, 1979. He skied at altitudes of up to 3300 m that day and the next, in spite of increasing headache, nausea, and dyspnea. Despite treatment with ampicillin and an expectorant for presumed bronchitis, he became progressively more dyspneic. On the morning of January 30 he was found on the floor, comatose, febrile (38.8°C), cyanotic, and incontinent of urine. Ten liters of oxygen per minute was administered, and he was taken in a helicopter to the hospital; his condition improved rapidly on descent into Denver (altitude, 1600 m). On admission to the hospital, he was lethargic, confused, and ataxic. Respirations were 32 per minute, blood pressure was 150/90 mm Hg, and rales were present over the entire left chest. He appeared dehydrated, and the urinary specific gravity was 1.030. A sample of arterial blood with the patient breathing oxygen through a non-rebreathing reservoir mask showed that the partial pressure of oxygen (PaO<sub>2</sub>) was 45 mm Hg, the partial pressure of carbon dioxide (PaCO<sub>2</sub>) 29 mm Hg, and the pH 7.43 (normal values during air breathing at 1600 m are PaO<sub>2</sub>, 65 to 70 mm Hg; PaCO<sub>2</sub>, 34 to 38 mm Hg; and pH, 7.38 to 7.42). A lumbar puncture was performed

From the Cardiovascular Pulmonary Research Laboratory, University of Colorado Health Sciences Center, Denver; the Lutheran Medical Center, Denver; the Department of Emergency Medicine, Denver General Hospital; the University of Vermont, Burlington; Breckenridge, Colo.; and the Summit County Clinic, Dillon, Colo. (address reprint requests to Dr. Reeves at the Cardiovascular Pulmonary Research Laboratory, University of Colorado Health Sciences Center, 4200 E. Ninth Ave., Denver, CO 80262).

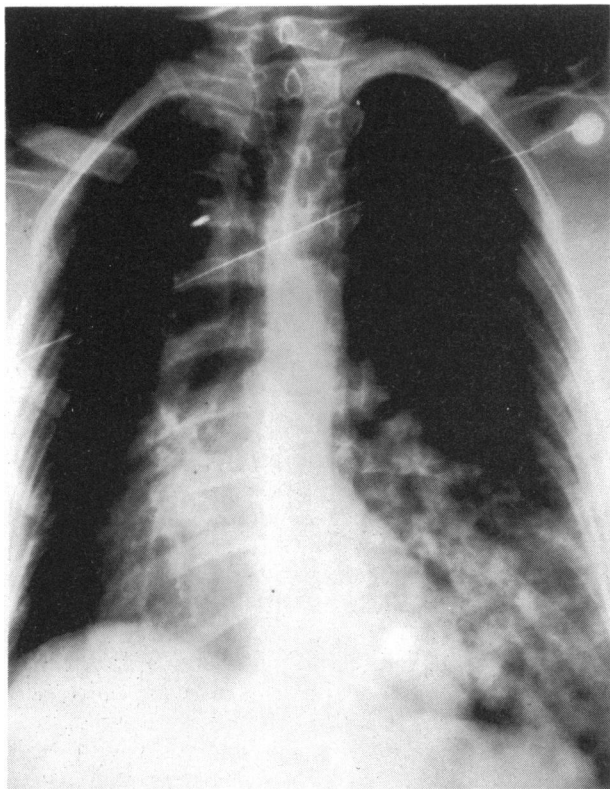


Figure 1. Admission X-Ray Film from Patient 1.

Note infiltrates in the left chest, small right hemithorax, shift of the mediastinum to the right, and asymmetrical vascular markings.

because of marked meningismus, and the opening pressure was 220 mm Hg. An x-ray film of the chest (Fig. 1) revealed extensive infiltrate in the left lower lobe, no infiltrate on the right, a shift of the mediastinum to the right, and a small right hemithorax. There was no pulmonary-artery shadow on the right. The patient was treated with high-flow oxygen and antibiotics. His neurologic and pulmonary symptoms cleared during the next three days. Perfusion lung scans with [<sup>131</sup>I]albumin revealed perfusion of the left but not the right lung (Fig. 2). On the seventh hospital day a sample of arterial blood drawn with the patient breathing air showed that the PaO<sub>2</sub> was 72 mm Hg, the PaCO<sub>2</sub> 30 mm Hg, and the pH 7.45.

#### Patient 2

A 56-year-old woman from Kansas arrived in Dillon, Colo. (altitude, 2750 m), on June 30, 1972. On the following day she noted exertional dyspnea. By the evening of the third day she was severely ill, with dyspnea at rest, a dry cough, severe headache, fever, and mild diarrhea. A local physician noted cyanosis, tachypnea, and moist rales over the left side of the chest. She was given oxygen to breathe at 7 liters per minute but gradually became worse during the next 10 hours; in addition to persistent rales in the left side of the chest, rales also developed in the region of the right lung base. She was transferred to Denver, and she improved with the descent. A chest x-ray showed pulmonary edema on the left, no right-pulmonary-artery shadow, a small right hemithorax, and a shift of the mediastinum to the right. Arterial blood drawn while the patient was breathing oxygen at 4 liters per minute showed that the PaO<sub>2</sub> was 52 mm Hg, the PaCO<sub>2</sub> 28 mm Hg, and the pH 7.5. A lung scan with [<sup>131</sup>I]albumin showed perfusion of the left lung but not the right. She was given diuretics, and oxygen therapy was continued. After three days the x-ray film of the chest showed clearing of the infiltrates. An arterial blood sample drawn while she breathed room

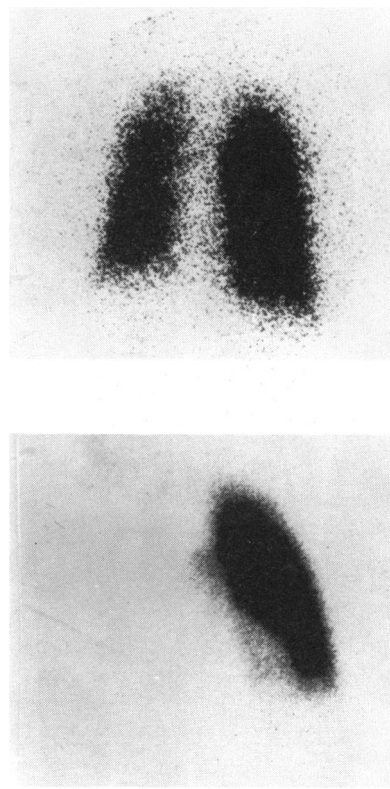


Figure 2. Ventilation Lung Scan (Top) and Perfusion Lung Scan (Bottom) on the Fourth Hospital Day from Patient 1.

Note absence of perfusion on the right.

air showed that the PaO<sub>2</sub> was 65 mm Hg, the PaCO<sub>2</sub> 35 mm Hg, and the pH 7.49.

In January 1974, cardiac catheterization was performed at sea level. The pulmonary-artery pressure at rest was elevated to 44/17 mm Hg with a mean of 28 mm Hg; it increased further to 75/37 mm Hg after two minutes of mild exercise with the patient supine. Pulmonary-artery wedge pressure was 12/6 mm Hg at rest; it was not measured during exercise. Left ventricular end-diastolic pressure was 8 mm Hg, and an angiogram showed normal left ventricular contractions. A pulmonary angiogram showed pulmonary flow only to the left lung (Fig. 3). The right lung was supplied by branches from the coronary artery, right subclavian artery, and abdominal aorta.

#### Patient 3

A 23-year-old man from Rapid City, S.D., arrived in Dillon, Colo., on March 15, 1975. On March 17, he skied at Winter Park (altitude, 2750 m), and during that evening he noted difficulty in sleeping owing to dyspnea. On the next morning, he skied at Steamboat Springs (altitude, 1950 m) and noted marked exertional dyspnea, nonproductive cough, and difficulty in sleeping that night. On the morning of March 19, because of dyspnea, cough, hemoptysis, and cyanosis, he was taken to a hospital in Denver with a diagnosis of pneumonia. X-ray films of the chest taken on admission showed infiltrates in the left lung but not in the right lung. The right hemithorax was small, and there was no visible right pulmonary artery. A pulmonary arteriogram and an x-ray film of the chest taken in 1971 had shown an absence of the right pulmonary artery. A sample of arterial blood with the patient breathing oxygen at 4 liters per minute revealed that the PaO<sub>2</sub> was 45 mm Hg, the PaCO<sub>2</sub> 28 mm Hg, and the pH 7.46. A lung scan with [<sup>131</sup>I]albumin showed no perfusion on the right. The x-ray film of the chest continued to show

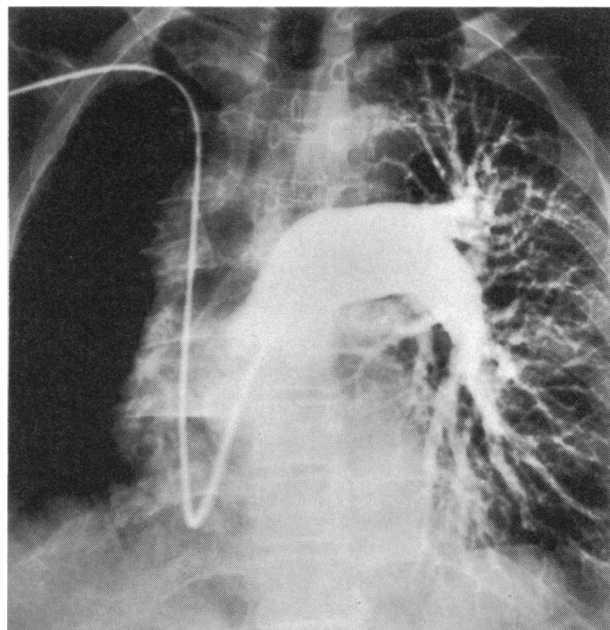


Figure 3. Pulmonary Angiogram from Patient 2, 18 Months after Pulmonary Edema.  
Note filling on the left only.

pulmonary edema of the left lung on the fourth hospital day, but the edema had resolved on the eighth day.

#### Patient 4

A 21-year-old man from Missouri arrived by car in Breckenridge, Colo. (altitude, 2900 m), on the evening of January 1, 1975. On the next morning after making only a single ski run, he noted malaise and returned to the lodge, thinking that he had the flu. Nausea and vomiting developed, and he slept poorly because of dyspnea and cough. On January 3, he remained in bed but had orthopnea. Because of worsening dyspnea, poor color, and confusion, at 7 p.m. he was taken to a nearby clinic but was dead on arrival. A post-mortem x-ray film of the chest revealed massive pulmonary infiltrates, greater on the left, a small right hemithorax, a shift of the mediastinum to the right, and no pulmonary-artery shadow on the right. Autopsy showed congenital absence of the right pulmonary artery, with enlarged bronchial arteries to the right lung. There was bilateral pulmonary edema, more pronounced on the left, but pneumonia was absent and post-mortem cultures of the edema fluid were negative. The right ventricular wall was thickened and measured 8 mm, whereas the left measured 20 mm. There were no other cardiac abnormalities.

#### DISCUSSION

We have described four cases of a life-threatening illness that developed in visitors to moderate altitudes. In three of these patients, the time sequence of symptoms after arrival at moderate altitude, the rapid resolution with descent and oxygen, the x-ray films of the chest, and the abnormalities in arterial blood gas all confirmed the diagnosis of high-altitude pulmonary edema. In the fourth patient, who had similar symptoms, pulmonary edema was confirmed at autopsy.

Absence of the right pulmonary artery in our patients was established in one at autopsy, in two with pulmonary angiography, and in one with perfusion

lung scanning. All had roentgenographic evidence that the right main pulmonary artery was absent. Elder et al.<sup>3</sup> have suggested that a presumptive diagnosis can be made on the basis of the typical chest x-ray findings alone.<sup>4</sup> Absence of the pulmonary artery probably represents a congenital anomaly, but a thrombosis or embolism occurring early in life could not be excluded except in the patient examined at autopsy.

The incidence of life-threatening pulmonary edema in visitors to Colorado is unknown but is probably low. In the winter of 1978-1979, for example, 34 patients required hospitalization or transfer to a lower altitude from three of the ski areas in Summit County. Although the exact size of the population at risk cannot be determined, we estimate from available statistics that the incidence is between one and 10 per 10,000 among persons spending several days and nights above 2700 m. Unilateral absence of a pulmonary artery is less common. There were only 32 cases without associated cardiac defects reported in a review of the world's literature in 1962,<sup>5</sup> and there have been 15 subsequent cases.<sup>6</sup> Our report adds four more. None of our four subjects had evidence of other cardiac abnormalities, and before exposure to high altitude all had considered themselves in good health, with no history of lung disease. Hence, our four patients constitute an unusually large group with this rare condition. Since all four had high-altitude pulmonary edema, which is in itself an uncommon condition, it is unlikely that the concurrence of these two conditions is due to chance. Rather, it seems likely that altitude edema in persons lacking one pulmonary artery may be extremely high.

Pulmonary hypertension may have been present before the pulmonary edema. Persons with congenital absence of a pulmonary artery as an isolated anomaly frequently have pulmonary hypertension.<sup>5</sup> In the patient examined at autopsy, the right ventricular hypertrophy was presumptive evidence of pulmonary hypertension, and in the one patient of ours in whom hemodynamic measurements were made, mild pulmonary hypertension was present at rest and became severe with exercise. Medial hypertrophy has been reported in the small pulmonary arteries of patients lacking one pulmonary artery, suggesting hyperreactivity.<sup>7</sup> When one pulmonary artery was ligated in newborn calves at sea level, pulmonary hypertension did not develop until the calves were brought to Denver (altitude, 1600 m), implying an excessive pulmonary vascular response to mild hypoxia.<sup>8</sup> Furthermore, exercise can cause an exaggerated rise in pulmonary-artery pressure, as demonstrated in one of our patients and as shown by others.<sup>3</sup> All our patients exercised before symptoms developed. Hence, it is likely that these four patients had pulmonary hypertension at moderate altitudes and that the hypertension increased with exercise.

A number of studies have implicated pulmonary hypertension in the development of altitude edema.

Seven persons subjected to right-heart catheterizations during high-altitude pulmonary edema had an average mean pulmonary-artery pressure of 58 mm Hg.<sup>9-11</sup> When subjects with a history of the disorder were brought to higher altitude, excessive pulmonary hypertension (mean pressure of 39±10 mm Hg) developed before the onset of symptoms or findings of edema,<sup>12</sup> and the pressure rose to 53±12 mm Hg during exercise. In addition, Viswanathan et al. have shown exaggerated pulmonary hypertension in response to acute hypoxia at sea level in men known to be susceptible.<sup>13</sup>

Total cardiac output was normal in the patient of ours in whom it was measured, and in previous reports it has been normal or high. Since the entire cardiac output passes through only one lung, the implication is that the blood flow through that lung was at least twice the normal flow, even at rest. Visscher<sup>14</sup> and Hultgren<sup>2</sup> have proposed that the distribution of pulmonary vascular resistance may become uneven during hypoxic pulmonary vasoconstriction and that the areas of lower resistance, which are overperfused, are the areas that develop edema. This concept was recently supported by evidence of uneven lung perfusion detected by means of radionuclide scanning in men susceptible to high-altitude pulmonary edema who were breathing hypoxic gas mixtures at sea level.<sup>15</sup> Overperfusion edema has also been described in patients with hypertensive encephalopathy.<sup>16</sup> Since our patients already have an overperfused lung at sea level, they would be particularly susceptible to development of areas of overperfusion edema during uneven vasoconstriction induced by high-altitude hypoxia. Furthermore, the high flow could induce endothelial damage, as proposed by Flick et al.<sup>17</sup> and Hyers et al.<sup>18</sup> The present evidence favors both high pressure and high flow as important factors in the pathogenesis of high-altitude pulmonary edema. This hypothesis is not weakened by the finding of some edema in the right lung (without a pulmonary artery) in two of our patients, since this edema could well have resulted from aspiration of edema fluid that originated in the left lung.

Physicians should be aware that the absence of a pulmonary artery can be diagnosed with an x-ray film of the chest, that high altitude can be very hazardous for persons with such an anomaly, and that any severe form of high-altitude illness at only moderate altitude should raise the suspicion that there is a predisposing factor.

We are indebted to Drs. J. Oberheide and J. Riopelle for reviewing their records, to Dr. W. B. Galloway for performing the autopsy in Patient 4, to Dr. D. McConahay for performing the heart catheterization in Patient 2, and to B. Fluitt for preparing the manuscript.

#### REFERENCES

1. Grover RF, Hyers TM, McMurtry IF, Reeves JT. High altitude pulmonary edema. In: Fishman AP, Renkin EM, eds. *Pulmonary edema*. Bethesda: American Physiological Society, 1979:229-40.
2. Hultgren HN. High altitude pulmonary edema. In: Staub NC, ed. *Lung water and solute exchange*. New York: Marcel Dekker, 1978:437-69.

3. Elder JC, Brofman BC, Kohn PM, Charms BL. Unilateral pulmonary artery absence or hypoplasia: radiographic and cardiopulmonary studies in five patients. *Circulation*. 1958; 17:557-66.
4. Wyman SM. Congenital absence of a pulmonary artery: its demonstration by roentgenography. *Radiology*. 1954; 62:321-8.
5. Pool PE, Vogel JHK, Blount SG Jr. Congenital unilateral absence of a pulmonary artery: the importance of flow in pulmonary hypertension. *Am J Cardiol*. 1962; 10:706-31.
6. Shakibi JG, Rastan H, Nazarian I, Paydar M, Aryanpour I, Siassi B. Isolated unilateral absence of the pulmonary artery: review of the world literature and guidelines for surgical repair. *Jpn Heart J*. 1978; 19:439-51.
7. Wagenvoort CA, Wagenvoort N. *Pathology of pulmonary hypertension*. New York: John Wiley, 1977:294.
8. Vogel JHK, McNamara DG, Hallman G, Roseberg H, Jamieson G, McCrady JD. Effects of mild chronic hypoxia on the pulmonary circulation in calves with reactive pulmonary hypertension. *Circ Res*. 1967; 21:661-9.
9. Penalzoza D, Sime F. Circulatory dynamics during high altitude pulmonary edema. *Am J Cardiol*. 1969; 23:369-78.
10. Hultgren HN, Lopez CE, Lundberg E, Miller H. Physiologic studies of pulmonary edema at high altitude. *Circulation*. 1964; 29:393-408.
11. Fred HL, Schmidt AM, Bates T, Hecht HH. Acute pulmonary edema of altitude: clinical and physiologic observations. *Circulation*. 1962; 25:929-37.
12. Hultgren HN, Grover RF, Hartley LH. Abnormal circulatory responses to high altitude in subjects with a previous history of high-altitude pulmonary edema. *Circulation*. 1971; 44:759-70.
13. Viswanathan R, Jain SK, Subramanian S, Subramanian TAV, Dua GL, Giri J. Pulmonary edema of high altitude. II. Clinical, aerodynamic, and biochemical studies in a group with history of pulmonary edema of high altitude. *Am Rev Respir Dis*. 1969; 100:334-41.
14. Visscher MB. Studies on embolization of lung vessels. In: Grover RF, ed. *Normal and abnormal pulmonary circulation*. Basel: S Karger, 1963:152.
15. Viswanathan R, Subramanian S, Radha TG. Effect of hypoxia on regional lung perfusion, by scanning. *Respiration*. 1979; 37:142-7.
16. Lassen NA. Control of cerebral circulation in health and disease. *Circ Res*. 1974; 34:749-60.
17. Flick MR, Perel A, Kageler W, Staub NC. White blood cells contribute to increased lung vascular permeability after microemboli. *Fed Proc*. 1979; 38:1265. abstract.
18. Hyers TM, Martinez A, Grover RF, Reeves JT. Hypoxic exercise-induced lung injury in rats. *Fed Proc*. 1978; 37:292. abstract.

### BREAST MILK AND THE RISK OF CYTOMEGALOVIRUS INFECTION

SERGIO STAGNO, M.D.,  
DAVID W. REYNOLDS, M.D.,  
ROBERT F. PASS, M.D.,  
AND CHARLES A. ALFORD, M.D.

**D**ESPITE increasing interest, the modes of transmission of cytomegalovirus (CMV) infection, particularly in the first year of life, remain ill-defined. During the first year the rate of acquisition of CMV infection throughout the world is variable but high, as summarized in Table 1.<sup>1-10</sup> In populations of different ethnic and socioeconomic backgrounds, from 8 to 60 per cent of infants begin shedding virus into the urine during the first year. Intrauterine transmission, although common (it accounts for 0.4 to 2.5 per cent of cases), cannot account for the high rates of perinatal

From the departments of Pediatrics and Microbiology, the University of Alabama in Birmingham (address reprint requests to Dr. Stagno at the University of Alabama in Birmingham, Department of Pediatrics, Room 609 CDLD Building, University Station, Birmingham, AL 35294).

Supported by a grant from the National Institutes of Child Health and Human Development (5 P01-HD 10699), a General Clinical Research Grant (5 M01-RR 32), and the Robert E. Meyer Foundation.