

High Altitude Cerebral Edema

PETER H. HACKETT¹ and ROBERT C. ROACH²

ABSTRACT

Hackett, Peter H., and Robert C. Roach. High altitude cerebral edema. *High Alt. Med. Biol.* 5:136–146, 2004.—This review focuses on the epidemiology, clinical description, pathophysiology, treatment, and prevention of high altitude cerebral edema (HACE). HACE is an uncommon and sometimes fatal complication of traveling too high, too fast to high altitudes. HACE is distinguished by disturbances of consciousness that may progress to deep coma, psychiatric changes of varying degree, confusion, and ataxia of gait. It is most often a complication of acute mountain sickness or high altitude pulmonary edema. The current leading theory of its pathophysiology is that HACE is a vasogenic edema; that is, a disruption of the blood–brain barrier, and we review possible mechanisms to explain this. Treatment and prevention of HACE are similar to those for the other altitude illnesses, but with greater emphasis on descent and steroids. We conclude the review with several case histories to illustrate key clinical features of the disorder.

Key Words: vasogenic; cytotoxic; cerebrospinal fluid pressure; brain swelling

INTRODUCTION

HIGH ALTITUDE CEREBRAL EDEMA (HACE) is a mysterious and infrequent malady brought about by exposure to the thin air of high altitude. We define it as a condition occurring in persons who have recently arrived at high altitude, usually secondary to acute mountain sickness or high altitude pulmonary edema, and marked by disturbances of consciousness that may progress to deep coma, psychiatric changes of varying degree, confusion, and ataxia of gait. Although uncommon, HACE causes significant morbidity and occa-

sionally death in otherwise perfectly healthy people. Most experts consider HACE, both clinically and pathophysiologically, an extension of acute mountain sickness (AMS); the distinction between HACE and advanced AMS is therefore inherently imprecise. Clinically, HACE is an encephalopathy, while AMS is not. In this brief paper we review clinical aspects of HACE and discuss current concepts of pathophysiology and treatment. In contrast to many recent reviews on acute mountain sickness or altitude illness in general, this is the first specific review of HACE in 20 years (Dickinson, 1983).

¹International Society for Mountain Medicine and Colorado Center for Altitude Medicine and Physiology, Ridgeway, Colorado.

²Colorado Center for Altitude Medicine and Physiology, University of Colorado Health Sciences Center, Aurora, Colorado.

EPIDEMIOLOGY AND RISK FACTORS

HACE occurs in unacclimatized persons at altitudes above 2000 m and most commonly with abrupt ascent to over 3000 m. The lowest reported altitude of occurrence is 2100 m (Dickinson, 1979). Less commonly, it also occurs at extreme altitude (over 7000 m) in climbers apparently well acclimatized (Clarke, 1988). Due to differences in definition and clinical diagnosis, limited epidemiological research, and wide range of rate of ascent, the exact incidence of HACE is not clear. Hackett and Rennie (1976) reported HACE in 1.0% of all trekkers between 4243 and 5500 m in Nepal, but HACE increased to 3.4% in those who suffered AMS. Bärtsch mentioned an incidence of 0.5% in 5355 visitors to 4555 m in Tibet, as reported to him by Tianyi Wu (Bärtsch and Roach, 2001). Basnyat et al. (2000), using a questionnaire, reported the astonishing figure of 31% of Vedic pilgrims in Nepal with HACE at 4300 m. This is a far higher incidence than any other study, but it was in the setting of a most unusual ascent profile; rarely do so many persons ascend in two days from 2000 to 4300 m to sleep at that altitude. Nonetheless, a more comprehensive study including neurological exam is necessary to verify these findings.

HACE is much more likely in those with high altitude pulmonary edema. Gabry et al. (2003) found that 13% of 52 patients with HAPE in the French Alps had stupor or coma. Hultgren et al. (1996) reported that 14% of 150 patients with HAPE in the Colorado Rockies had HACE, and 20% of 50 HAPE patients evacuated by helicopter in the Swiss Alps also had HACE (Hochstrasser et al., 1986). Autopsy studies reveal that 50% of those dying with HAPE also had HACE. Conversely, HAPE is common in those identified with HACE. In a series from the Colorado Rocky Mountains, 11 of 13 patients admitted to hospital with HACE had HAPE (Yarnell et al., 2000). Although the exact incidence of HACE is unclear, it is less common than HAPE, except in one study (Basnyat et al., 2000) and much less common than AMS. Whether all patients with HACE develop AMS first is unclear; certainly, that is the usual case. However, abrupt onset of HACE is occasionally reported, especially at extreme altitude. Whether this re-

flects a lack of early recognition of prodromal symptoms or rapid onset *de novo* is not clear; this presentation is particularly dangerous (Clarke, 1988); see the case examples at the end of this paper. The speed of progression from AMS to HACE varies. Most commonly, HACE develops as a progression of AMS over 24 to 36 h, either independently of HAPE or as HAPE develops concomitantly. Occasionally, AMS progresses to HACE within a few hours. The mean altitude of onset of HACE in one literature review was 4730 m, but was lower (3920 m) when associated with HAPE (Hultgren, 1997).

Since HACE is apparently an extension of AMS and also occurs commonly with HAPE, the risk factors for HACE are the same as those for AMS and HAPE (see the reviews by Bärtsch and Schoene in this issue). These include a rapid ascent to altitude, exertion, a past history of high altitude illness, perhaps a genetic predisposition, and, for HAPE, certain preexisting abnormalities of the pulmonary circulation. For example, the high incidence of HACE in the Basnyat study was attributed to the rapid rate of ascent: 68% developed AMS by the Lake Louise criteria (Basnyat et al., 2000). Data regarding the influence of age and gender are scant. Reports of HACE in children are rare, perhaps reflecting the small population of children making rapid ascent to high altitude. Unlike HAPE, no preexisting physiological abnormalities have yet been identified as risk factors for AMS or HACE, except perhaps space-occupying intracranial masses or cysts (Hackett, 2000). Some have suggested that random anatomical differences might explain a tendency to AMS and HACE (Ross, 1985); see the section later on pathophysiology. Unlike HAPE, no one has yet investigated possible genetic predisposing factors, such as vascular endothelial growth factor (VEGF) polymorphisms or the genetics of the cerebral circulatory response to hypoxia (see pathophysiology).

CLINICAL PRESENTATION AND DIAGNOSIS

Change in consciousness and ataxic gait herald the onset of HACE. Typically, symptoms of AMS have been progressing over the previous

24 to 48 h. Headache is often but not always present. Drowsiness and subtle psychological changes appear first. The victim is often withdrawn and apathetic. Lassitude progresses from apparent laziness to being completely unable to care for oneself, for example, not caring to dress appropriately for the conditions, not bothering to eat or drink, and sleeping outside a sleeping bag. Confusion becomes evident, usually in tandem with ataxia. Anorexia is nearly always present, while nausea is common and vomiting is less common (Dickinson, 1983). Case reports have mentioned both auditory and visual hallucinations, but these are uncommon (Oelz and Largiader, 1987). Seizures appear to be rare. One author has suggested, "If the patient seems mildly drunk at altitude they have cerebral edema" (Clarke, 1988). Indeed, mild ataxia and dulled sensorium should certainly raise the suspicion of HACE. Coma was present in 16 of 44 patients in one series, while consciousness was described as normal in 13 of the 44 (Dickinson, 1981). In another series of 20 patients from Ladakh, 12 were in coma (Norboo et al., 1998). The high incidence of coma in these series is due in part to prolonged transport to hospital and to achieve descent.

Physical findings are variable, with disturbed consciousness and ataxia being the most common. Table 1 lists the neurological findings in the largest series published to date (Dickinson, 1983). In this same series, retinal hemorrhages were present in 59% of those with HACE, but the most seriously ill did not have hemorrhages. Since retinal hemorrhages are

common at altitudes over 5000 m and not necessarily associated with altitude illness, their presence is not diagnostic of HACE (Hackett and Roach, 2001a). Others have suggested, however, that careful funduscopy revealing a progression of retinal pathology at altitude is an indication of impending HACE (Wiedman and Tabin, 1999).

Many other conditions are easily confused with HACE (see Table 2). Onset of illness after 3 days at a stable altitude, abrupt onset, trauma, focal neurological signs, high fever, stiff neck, and lack of response to treatment should all mandate consideration of other diagnoses. For example, this past summer, a climber on Denali was diagnosed with HACE; did not respond well to steroids, oxygen, and descent; and was later found to have episodic hypoglycemia from an insulin-secreting tumor. One of the authors (PH) has recently consulted on five patients diagnosed with HACE in Colorado who turned out instead to have severe hyponatremia; one died. Also in Colorado, a large malpractice settlement resulted from an incorrect diagnosis of HACE in a man subsequently diagnosed with herpes encephalitis. The clinician must be careful to do a complete history and physical exam, with appropriate laboratory studies to rule out other conditions when feasible. Except in mild cases with rapid, complete recovery, patients with HACE should probably be hospitalized and receive a complete evaluation, including measurements of serum electrolytes and renal function, an MRI, and usually a lumbar puncture with appropriate CSF studies to rule out infection. Because of the association of HACE and HAPE, a chest radiograph should be obtained. In the field, abnormally low oxygen saturation by pulse oximetry in someone with HACE is sufficient evidence for the presumption of HAPE. In patients severely ill and requiring hospitalization, 11 of 13 in one series had concomitant HAPE (Yarnell et al., 2000).

Imaging studies may be helpful for diagnosis, but are not always necessary. CT images demonstrate attenuation of signal, either diffusely or in the white matter, with compression of sulci and flattening of gyri. MRI is more valuable both to identify the characteristic findings to confirm

TABLE 1. FREQUENCY OF NEUROLOGIC FEATURES IN 44 PATIENTS WITH HACE

Disturbance of consciousness	31 (70%)
Ataxia	27 (61%)
Papilledema	23 (52%)
Urinary retention or incontinence	21 (48%)
Abnormal plantar reflexes	15 (34%)
Abnormal limb tone and power	6 (14%)
Abducens nerve palsy	2
Pupil difference	2
Visual field loss	2
Speech difficulty	1
Hearing loss	1
Flapping tremor	1

From Dickinson, 1983.

TABLE 2. DIFFERENTIAL DIAGNOSIS OF HIGH ALTITUDE CEREBRAL EDEMA

Acute psychosis	Hypoglycemia
Brain tumor	Hyponatremia
Carbon monoxide poisoning	Hypothermia
Central nervous system infection	Ingestion of drugs, alcohol, or toxins
Cerebrovascular bleed or infarct	Migraine
Cerebrovascular spasm	Seizure disorder
Diabetic ketoacidosis	Transient ischemic attack

HACE and to exclude other pathology. T-2 and especially diffusion-weighted MR imaging reveals increased signal in the white matter, particularly in the splenium of the corpus callosum (see Fig. 1). While this finding is not pathognomonic, in the setting of recent ascent to altitude, it can be considered confirmatory. Since the MR findings may lag behind clinical recovery, MRI may be useful for diagnosis even after clinical improvement. In the only series of consecutive HACE patients studied with MRI, 7 of 9 patients with clinical HACE demonstrated the typical T-2 findings (Hackett et al., 1998). A subsequent patient of these investigators with a negative standard MRI demonstrated increased signal on diffusion-weighted MRI, raising the possibility

that the two patients with negative MRI in their initial series (Hackett et al., 1998) may have had a positive MRI if diffusion-weighted imaging had been employed. Flair sequences, apparent diffusion coefficient measurements, and other newer MR techniques may further improve the diagnostic utility of MRI for HACE (Wieshmann et al., 1996; Wieshmann et al., 1999; Lansberg et al., 2000; Hergan et al., 2002; Provenzale et al., 2002; Dong et al., 2004)

Lumbar puncture is sometimes necessary to exclude infection or subarachnoid hemorrhage. Opening pressure will usually be high; values from 44 to 220 mmH₂O have been reported (Singh et al., 1969; Houston and Dickinson, 1975). Fluid analysis is most often completely

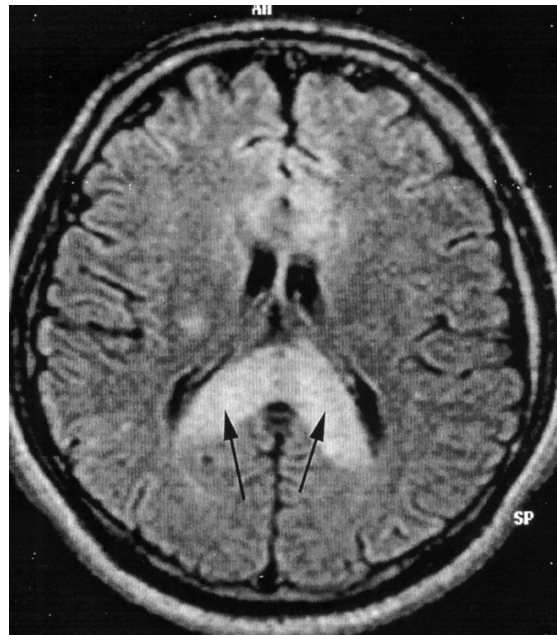


FIG. 1. MRI showing marked swelling and hyperintense posterior body and splenium of corpus callosum on T2 image (dark arrows) in a HACE case that went on to full recovery. Image courtesy of Dr. Buddha Basnyat.

normal; lymphocytes were reported in one case. A new MRI technique for estimating intracranial pressure promises a noninvasive measurement useful to both researchers and clinicians (Alperin et al., 2000). No laboratory studies are useful for confirming HACE, although they may exclude other diagnoses. The peripheral blood white cell count may be normal or high (Dickinson, 1981).

THE PATHOPHYSIOLOGICAL PROCESSES LEADING TO HACE

The link between cerebral edema and severe neurological dysfunction at high altitude was proposed by Mosso in 1898, first confirmed by Singh in 1965 from autopsy of two soldiers who died of HACE, and has been repeatedly observed since. Subsequently, several competing theories have evolved to explain the pathophysiology. At present, the leading theory is that HACE is a vasogenic edema; that is, a disruption of the blood-brain barrier, as discussed later. How AMS relates to HACE is still a matter of much speculation. In this review we identify the major gaps in our knowledge of the pathophysiology of HACE, and also in the spectrum of changes from AMS to HACE, and propose several unique approaches to advance our understanding in each area.

PATHOLOGICAL FINDINGS IN HACE

Lumbar punctures have revealed elevated CSF pressures in HACE, often more than 200 mmH₂O. CT scans and MRI have shown cerebral edema (Matsuzawa et al., 1992; Hackett et al., 1998), and necropsies have documented gross cerebral edema (Singh et al., 1969; Dickinson, 1983). End-stage findings from autopsy reports include small petechial hemorrhages, venous sinus thromboses, and other thromboses (Dickinson, 1983). Thrombosis is absent on brain scans in recovering HACE cases, confirming thrombosis as a terminal event. Thus, the pathophysiology of HACE includes brain edema and raised intracranial pressure.

Insights into the cause of the cerebral edema come from a recent series of MR imaging stud-

ies in HACE patients revealing edema in the white matter corpus callosum, with no gray matter edema, leading the authors to propose a vasogenic origin for the edema (Hackett et al., 1998). Other evidence supporting a vasogenic mechanism includes the time course of both onset and resolution, the fact that patients recover completely, response to steroids, and tissue and cell experiments showing increased permeability of cerebral endothelium exposed to hypoxia. The possibility must be considered that cytotoxic edema may coexist with vasogenic edema in the pathogenesis of HACE. Definitive imaging studies to distinguish cytotoxic from vasogenic edema during HACE and its resolution will be necessary to answer this question. However, we propose that any model to explain the pathophysiology of HACE must in the first instance account for vasogenic edema.

MECHANISMS ACCOUNTING FOR VASOGENIC EDEMA

Potential mechanisms to explain vasogenic edema include mechanical factors leading to blood-brain barrier (BBB) breakdown, biochemical mediators of BBB permeability, or both. These concepts are summarized briefly here, with inclusion of several new and potentially revealing approaches. More detailed reviews are available elsewhere (Krasney, 1994; Hackett, 1999; Hossmann, 1999; Hackett and Roach, 2001b; Roach and Hackett, 2001; Pardridge, 2003).

Vasogenic edema can result from cerebral capillary hypertension, as for example in hypertensive encephalopathy and toxemia of pregnancy. These reversible conditions, associated with increased white matter T2 signal, are associated with impaired cerebral autoregulation. At high altitude, there is mixed evidence for impaired autoregulation (Levine et al., 1999; Jansen et al., 2000; Ter Minassian et al., 2001). Further studies of autoregulation in persons at altitude, including those developing AMS as well as healthy subjects and high-altitude natives, will help to clarify this issue.

Cerebral capillary hypertension may also result from any impairment of cerebral venous return, especially during hypoxia-induced cere-

bral vasodilatation. HAPE may be a case in point, because of increased intrathoracic pressure. For example, Oelz (1983) invoked a change in venous pressure to explain the onset of HACE with coma after he treated his mild altitude pulmonary edema with a PEEP mask set to 10 cmH₂O. Random anatomical differences may also play a role in capillary hypertension. Recently, an anatomical abnormality leading to restriction of venous outflow was suggested as a predisposing factor to elevated ICP in idiopathic intracranial hypertension (Farb et al., 2003). Such an abnormality could also contribute to HACE and could help to explain the random individual susceptibility. Studies of cerebral venous anatomy and pressure in volunteers with AMS might be revealing.

Chemical mediators of permeability could by themselves cause vasogenic edema. Alternatively, in the presence of elevated cerebral capillary pressure, a small chemically mediated leak could have profound effects on brain edema. The interplay of mechanical and chemical mediators of BBB leak in vasogenic edema await further investigation. The same question of mechanical versus chemical permeability in the pulmonary circulation in HAPE has been answered in favor of mechanical factors. For HACE, these investigations are handicapped by the absence of a good animal model and the difficulty of assessing cerebral capillary pressure and brain biochemical processes in the intact human at altitude.

The list of potential chemical mediators of BBB leak in cerebral edema includes bradykinin, histamine, arachidonic acid, oxygen and hydroxyl free radicals, and perhaps iNOS-generated nitric oxide. Two other mechanisms remain very interesting and perhaps more amenable to study in human volunteers. First, Raichle et al. (1978) reported increased BBB permeability in an animal study secondary to stimulation of central noradrenergic output. Marked elevation of sympathetic outflow by hypoxia is well documented (see Reeves, 1993, for a review), and individual variation in the degree of sympathetic stimulation could play a role in BBB leak. Second, a role for vascular endothelial growth factor to explain elevated vascular permeability leading to vasogenic edema was first proposed by Severinghaus (1995).

Schoch and co-workers (2002) recently demonstrated two important findings in mice. First, hypoxia induced VEGF expression, and blocking that expression with a VEGF-specific antibody prevented vascular leakage in the brain. Second, dexamethasone appeared to prevent and reverse hypoxia-induced brain edema by blocking VEGF expression. These two findings suggest a VEGF-related mechanism at play in HACE. If true, then studying the genetics of VEGF in individuals might offer clues to HACE susceptibility.

THE LINK FROM AMS TO HACE

The clinical progression from the mild symptoms of AMS to severe, incapacitating headache and mild ataxia and on to HACE suggests a reasonable and testable link in the pathophysiology of AMS and HACE. One view holds that the cerebral edema seen in HACE begins already in mild AMS, causing high-altitude headache through a mechanical, swelling-induced stretching of pain-sensitive structures, such as the dura or meninges. Another view is that cerebral vasodilatation, rather than edema, leads to a swollen brain and causes AMS, and that edema subsequently develops in those who go on to HACE. In this model, neither edema nor brain swelling would have to proceed to the point of raising intracranial pressure to produce AMS. The normal arterial pulsation in the context of a brain with nearly exhausted cranial compliance because of vasodilatation, a so-called "stiff brain," could transmit any movement of intracranial contents to pain-sensitive regions. Alternatively, the tight-fit hypothesis, first proposed by Ross (1985), suggests variation in cranial buffering capacity could determine susceptibility to AMS via variations in intracranial pressure. The brain of a climber with excess buffering capacity could swell, with no net effect on intracranial pressure, compared to those with limited buffering capacity, where swelling due to any cause would lead to a greater rise in intracranial pressure. No studies have yet been reported that evaluate the tight-fit hypothesis.

Studies of the relationship of brain swelling to AMS, however, have revealed that all brains

swell on ascent to altitude (Morocz et al., 2001), presumably from vasodilatation, irrespective of AMS. However, these MR techniques were not capable of detecting small differences that could still be clinically significant. Moreover, no studies have evaluated the anatomical or dynamic components of the tight-fit hypothesis, in spite of the availability of quantitative imaging techniques. We disagree with our colleagues' view in the accompanying review on acute mountain sickness that available evidence is sufficient to dismiss the tight-fit hypothesis. We suggest that a definitive link between vasogenic edema in HACE and brain swelling in AMS will require serial measurements of changes in brain volume and compliance as volunteers progress from well to AMS and will require automated brain volume software such as the SIENA program (Smith et al., 2002). Using SIENA, changes of less than 1% in global brain volume can be reliably detected. Taken together, the available data suggest that the jury is still out regarding a pathophysiological link between AMS and HACE.

An alternative view is that headache in early AMS could be explained by trigeminal nerve pathway activation, similar to migraine. Sanchez del Rio and Moskowitz describe a model whereby neurogenic inflammation secondary to hypoxia could lead to trigeminovascular system activation and thereby to headache (Moskowitz, 1990; and Sanchez del Rio, 1999). This seems a reasonable hypothesis in light of the successful treatment and prevention of high altitude headache by drugs with antiinflammatory actions, such as aspirin (Broome et al., 1994; Burtscher et al., 1995; Burtscher et al., 2001), ibuprofen, and dexamethasone (Johnson et al., 1984; Ferrazzini et al., 1987; Hackett et al., 1988; Levine et al., 1989). Studies to explore this possibility could employ advanced neuro-imaging techniques currently being used to examine the underlying pathophysiology of migraine (Goadsby, 2002a, b).

CLINICAL COURSE AND TREATMENT

The clinical course varies with the severity of illness prior to treatment. Once coma has developed, death is more likely despite aggres-

sive therapy (Singh et al., 1969). Whether extent of edema on MR correlates with prognosis or time to resolution is unknown; in our experience it does not, as evidenced by the Fig. 1, in which this man, with extensive edema on MRI, had an uneventful and rapid recovery. The usual course is rapid recovery if treatment is started at the first sign of HACE and slower recovery when treatment is delayed. A hospital stay of 4 to 5 days for patients that are not ambulatory is common. Average hospital stay was 5.6 days in a recent series of 9 patients, whereas average time to recovery was 2.4 weeks, ranging from 1 day to 6 weeks (Hackett et al., 1998). In a series of 44 patients with HACE from 1983, 10 recovered in 2 days or less after evacuation from high altitude, 32 were in hospital for between 3 and 14 days, and 2 remained unconscious for over 3 weeks (Dickinson, 1983). Long-term follow-up was not available. We might expect shorter hospital stay and quicker recovery, as reflected in the more recent of these series, as recognition and diagnosis are improved and evacuation becomes easier. In Nepal, for example, immediate helicopter evacuation, once an uncommon luxury, is now readily available (Graham and Basnyat, 2001).

Treatment of HACE is similar to that for other altitude illnesses, with emphasis on oxygen and descent. Simulated descent with a hyperbaric bag can also be useful, as in all altitude illness (Austin, 1998; Zafren, 1998). Compared to AMS and HAPE, most authors have noted that HACE requires a greater descent and time to recovery is longer. All agree that early treatment is the key to success. In addition to descent and oxygen, standard treatment is to give steroids in large doses, usually dexamethasone 8 to 10 mg IV, IM, or PO, followed by 4 mg every 6 h. While no controlled trials will ever be done in humans with HACE, clinical experience certainly supports the use of steroids. Controlled trials have demonstrated the benefit of steroids in moderate to severe AMS and, given the presumed common pathophysiology, it is logical to use steroids in HACE. Patients in coma require airway management and bladder drainage. Attempting to decrease intracranial pressure by intubation and hyperventilation might be a reasonable ap-

proach, but these patients already have a respiratory alkalosis, and overventilation could result in cerebral ischemia; oxygen alone markedly reduces CBF and ICP at high altitude (Hartig and Hackett, 1992). Clinicians have used loop diuretics (furosemide 40 to 80 mg or bumetanide 1 to 2 mg) to reduce brain hydration, but no controlled studies exist. Since an adequate intravascular volume to maintain perfusion pressure is critical, careful monitoring to avoid hypotension with these agents is critical. Dickinson (1981) reported that in the many HACE patients he treated with at least a single dose of intravenous furosemide, hypovolemia was never a problem. Singh et al. (1969) reported a similar experience. Hypertonic solutions of saline, mannitol, and oral glycerol have been used in the hospital setting (Houston and Dickinson, 1975; Dickinson, 1983); experience with these agents in the field is quite limited. The physiological rationale for these agents seems sound. ICP monitoring during HACE has not yet been reported. While most patients who make it to the hospital alive make a complete recovery, prolonged recovery time and presumed permanent impairment have been reported (Houston and Dickinson, 1975; Dickinson, 1983; Hackett et al., 1998).

Prevention of HACE is the same as for all altitude illness: graded, reasonable rate of ascent, and, for HACE, avoidance of AMS and HAPE. At extreme altitude, onset of HACE may be abrupt, and prevention is not always possible. In recognition of this fact, many climbers are using dexamethasone on summit day for protection from HACE. While this apparently works for prevention of HACE, it has its own dangers due to the potential side effects of dexamethasone.

ILLUSTRATIVE CLINICAL EXAMPLES

Case 1

A 44-yr-old experienced climber-physician traveled from sea level to the high camp (5790 m) of Huyana Potosi in Bolivia in 5 days. At the refugio at 4708 m the night before, he slept poorly, but had no other symptoms of AMS. En route to high camp, he felt strong and had no pulmonary symptoms. After arrival at the

high camp, he developed headache, lassitude, anorexia, mild mental confusion, and ataxia over a period of 2 h; symptoms were progressing rapidly. He took 4 mg of oral dexamethasone, which slowed but did not stop progression of symptoms; 2.5 hours later, he took another 4 mg of oral dexamethasone, felt a bit better, and slept well. In the morning, he felt quite well, continued dexamethasone 4 mg every 6 h and was the first to the summit (6088 m). He made an uneventful descent. This case illustrates that HACE can develop abruptly and that, when used early, dexamethasone is remarkably effective. Whether continuing up while taking dexamethasone was a wise choice is arguable.

Case 2

A 50-yr-old male climber ascending Aconcagua developed headache, severe fatigue, and uncontrollable shivering at 4878 m. He also became claustrophobic in his tent. He began to take 125 mg of acetazolamide nightly. One rest day later he was better, but only made it halfway on the ascent to Camp 2 at 5854 m due to recurrence of headache, fatigue, and cold. After another rest day at 4878 m (Camp 1), he slowly made it to Camp 2 but was again "hypothermic" on arrival. He also felt dehydrated. He acclimatized after a rest day, but on the summit push he had headache and became ataxic and irrational at 6400 m; the guide administered balance tests, which he "failed," and although he felt euphoric, he was guided down to high camp at 6100 m. On the descent he started crying uncontrollably, then heard birds where there were none—first small birds then hawks. A few hours after arriving at Camp 3 he recovered. However, 2 months later, he still has little memory of the events other than the hallucinations. This example illustrates the potential difficulty of differentiating hypothermia from HACE. While both can present with ataxia and altered mental status, hallucinations, euphoria, and headache are much more likely to be due to HACE. This man did not take acetazolamide the night prior to the summit attempt. To our knowledge, no one has reported HACE in a person who was taking acetazolamide.

Case 3

A 48-yr-old European female ascended from 1500 to 5000 m in 5 days. She complained of a mild headache and had difficulty sleeping and poor appetite for 2 days prior to reaching the highest altitude. During the night at 5000 m, she became more ill, with somnolence and ataxia. In the morning she was in coma and remained so, despite a descent to 4230 m and administration of oxygen, furosemide, and steroids. Later that day she was evacuated by helicopter to hospital in Kathmandu. Her admission chest X ray was normal. She slowly regained consciousness over 3 days, was discharged 2 days later feeling mentally slow, and was amnesic for the events. This patient demonstrates a rather typical case history. Once coma has developed, response to treatment is not generally dramatic.

Case 4

A 27-yr-old male ascended from sea level to 2900 m for a ski vacation in Colorado. He developed headache, anorexia, and insomnia over the first 24 h, but skied the next day. That night, he developed a cough and was weak. The next day he was worse and stayed in the hotel. When his friends returned, they found him unconscious with gurgling respirations. He was taken to the local clinic where he was diagnosed with HAPE and HACE, and the doctor administered oxygen and dexamethasone. He started improving and was evacuated to a hospital at 1600 m. There he continued to improve. Radiograph of the chest revealed extensive pulmonary edema, and brain MRI revealed the classic increased T2-signal of the posterior corpus callosum. He was discharged 2 days later with only mild ataxia. It is common for ataxia to persist and be the last finding to resolve. The mechanism of ataxia in HACE is unknown; perhaps it is related to cerebellar dysfunction from hypoxia rather than edema per se.

REFERENCES

- Alperin N.J., Lee, S.H., Loth, F., Raksin, P.B., and Lichtor, T. (2000). MR-intracranial pressure (ICP): a method to measure intracranial elastance and pressure noninvasively by means of MR imaging: baboon and human study. *Radiology* 217(3):877-885.
- Austin D. (1998). Gamow bag for acute mountain sickness [letter]. *Lancet* 351(9118):1815.
- Bartsch P., and Roach R.C. (2001) Acute mountain sickness and high-altitude cerebral edema. In: *High Altitude: An Exploration of Human Adaptation*. T.F. Hornbein and R.B. Schoene, eds. Marcel Dekker, New York; pp. 731-776.
- Basnyat B., Subedi D., Sleggs J., Lemaster J., Bhasyal G., Aryal B., and Subedi N. (2000). Disoriented and ataxic pilgrims: an epidemiological study of acute mountain sickness and high-altitude cerebral edema at a sacred lake at 4300 m in the Nepal Himalayas. *Wilderness Environ. Med.* 11(2):89-93.
- Broome J.R., Stoneham, M.D., Beeley, J.M., Milledge J.S., and Hughes A.S. (1994). High altitude headache: treatment with ibuprofen. *Aviat. Space Environ. Med.* 65(1):19-20.
- Burtscher M., Likar, R., Nachbauer, W., Philadelphia M., Puhlinger R., and Lammle T. (2001). Effects of aspirin during exercise on the incidence of high-altitude headache: a randomized, double-blind, placebo-controlled trial. *Headache* 41(6):542-545.
- Burtscher M., Likar R., Nachbauer W., Schaffert W., and Philadelphia M. (1995). Ibuprofen versus sumatriptan for high-altitude headache (Letter). *Lancet* 346:254-255.
- Clarke, C. (1988). High altitude cerebral oedema. *Int. J. Sports Med.* 9:170-174.
- Dickinson, J. (1979). Severe acute mountain sickness. *Postgrad. Med.* 55:454-458.
- Dickinson, J. (1981). *Acute Mountain Sickness*. Radcliffe Library. Oxford University.
- Dickinson, J.G. (1983). High altitude cerebral edema: Cerebral acute mountain sickness. *Semin. Respir. Med.* 5:151-158.
- Dong Q., Welsh R.C., Chenevert T.L., Carlos R.C., Maly-Sundgren P., Gomez-Hassan D.M., and Mukherji S.K. (2004). Clinical applications of diffusion tensor imaging. *J. Magn. Reson. Imaging* 19(1):6-18.
- Farb R.I., Vanek I., Scott J.N., Mikulis D.J., Willinsky R.A., Tomlinson G., and terBrugge K.G. (2003). Idiopathic intracranial hypertension: the prevalence and morphology of sinovenous stenosis. *Neurology* 60(9):1418-1424.
- Ferrazzini G., Maggiorini M., Kriemler S., Bartsch P., and Oelz O. (1987). Successful treatment of acute mountain sickness with dexamethasone. *BMJ* 294:1380-1382.
- Gabry A.L., Ledoux X., Mozziconacci M., and Martin C. (2003). High-altitude pulmonary edema at moderate altitude (<2,400 m; 7,870 feet): a series of 52 patients. *Chest* 123(1):49-53.
- Goadsby P.J. (2002a). New directions in migraine research. *J. Clin. Neurosci.* 9(4):368-373.
- Goadsby P.J. (2002b). Headache. *Curr. Opinions Neurol.* 15(3):285-286.
- Graham L.E., and Basnyat B. (2001). Cerebral edema in the Himalayas: too high, too fast! *Wilderness Environ. Med.* 12(1):62.
- Hackett P.H. (1999). High altitude cerebral edema and

- acute mountain sickness: A pathophysiology update. In: Hypoxia: Into the Next Millennium. R.C. Roach, P.D. Wagner, and P.H. Hackett, eds. New York, Plenum/Kluwer Academic Publishing, New York; pp. 23–46.
- Hackett P.H. (2000). Subarachnoid cyst and ascent to high altitude—a problem? *High Alt. Med. Biol.* 1(4):337–339.
- Hackett P.H., and Rennie D. (1976). The incidence, importance, and prophylaxis of acute mountain sickness. *Lancet* 2(7996):1149–1155.
- Hackett P.H., and Roach R.C. (2001a). High-altitude medicine. In: *Wilderness Medicine*. P.A. Auerbach, ed. Mosby, St. Louis, MO; pp. 2–43.
- Hackett P.H., and Roach R.C. (2001b). Current concepts: high altitude illness. *New Engl. J. Med.* 345(2):107–114.
- Hackett P.H., Roach R.C., Wood R.A., Foutch R.G., Meehan R.T., Rennie D., and Mills W.J.J. (1988). Dexamethasone for prevention and treatment of acute mountain sickness. *Aviat. Space Environ. Med.* 59:950–954.
- Hackett P.H., Yarnell P.R., Hill R., Reynard K., Heit J., and McCormick J. (1998). High-altitude cerebral edema evaluated with magnetic resonance imaging: clinical correlation and pathophysiology [see comments]. *JAMA* 280(22):1920–1925.
- Hartig G.S., and Hackett P.H. (1992). Cerebral spinal fluid pressure and cerebral blood velocity in acute mountain sickness. In: *Hypoxia and Mountain Medicine*. J.R. Sutton, G. Coates, and C.S. Houston, eds. Queen City Press, Burlington, VT; pp. 260–265.
- Hergan K., Schaefer P.W., Sorensen A.G., Gonzalez R.G., and Huisman T.A. (2002). Diffusion-weighted MRI in diffuse axonal injury of the brain. *Eur. Radiol.* 12(10): 2536–2541.
- Hochstrasser J., Nanzer A., and Oelz O. (1986). “Das Hoehenoedem in den Schweizer Alpen.” *Schweiz. Med. Wschr.* 116:866–873.
- Hossmann K.A. (1999). The hypoxic brain: Insights from ischemia research. In: *Hypoxia: Into the Next Millennium*. R.C. Roach, P.D. Wagner, and P.H. Hackett, eds. Plenum/Kluwer Academic Publishing, New York; pp. 155–169.
- Houston C.S., and Dickinson J.G. (1975). Cerebral form of high altitude illness. *Lancet* 2:758–761.
- Hultgren H.N. (1997). *High Altitude Medicine*. Hultgren Publications, Stanford, CA.
- Hultgren H.N., Honigman B., Theis K., and Nicholas D. (1996). High-altitude pulmonary edema at a ski resort. *West. J. Med.* 164(3):222–227.
- Jansen G.F.A., Krins A., Basnyat B., Bosch A., and Odoom J.A. (2000). Cerebral autoregulation in subjects adapted and not adapted to high altitude. *Stroke* 31:2314–2318.
- Johnson T.S., Rock P.B., Fulco C.S., Trad L.A., Spark R.F., and Maher J.T. (1984). Prevention of acute mountain sickness by dexamethasone. *N. Engl. J. Med.* 310(11): 683–686.
- Krasney J.A. (1994). A neurogenic basis for acute altitude illness. *Med. Sci. Sports Exerc.* 26(2):195–208.
- Lansberg M.G., Norbash A.M., Marks M.P., Tong D.C., Moseley M.E., and Albers G.W. (2000). Advantages of adding diffusion-weighted magnetic resonance imaging to conventional magnetic resonance imaging for evaluating acute stroke. *Arch. Neurol.* 57(9):1311–1316.
- Levine B.D., Yoshimura K., Kobayashi T., Fukushima M., Shibamoto T., and Ueda G. (1989). Dexamethasone in the treatment of acute mountain sickness [see comments]. *N. Engl. J. Med.* 321(25):1707–1713.
- Levine B.D., Zhang R., and Roach R.C. (1999). Dynamic cerebral autoregulation at high altitude. *Adv. Exp. Med. Biol.* 474:319–322.
- Matsuzawa Y., Kobayashi T., Fujimoto K., Shinozaki S., and Yoshikawa S. (1992). Cerebral edema in acute mountain sickness. In: *High Altitude Medicine*. G. Ueda, J.T. Reeves, and M. Sekiguchi, eds. Shinshu University Press, Matsumoto, Japan; pp. 300–304.
- Morocz I.A., Zientara G.P., Gudbjartsson H., Muza S., Lyons T., Rock P.B., Kikinis R., and Jolesz F.A. (2001). Volumetric quantification of brain swelling after hypobaric hypoxia exposure. *Exp. Neurol.* 168(1):96–104.
- Moskowitz M.A. (1990). Basic mechanisms in vascular headache. *Neurol. Clin.* 8:801–815.
- Norboo T., Angchuk S.T., et al. (1994). *High altitude cerebral edema in Ladakh, in: Progress in Mountain Medicine and High Altitude Physiology*. The 3rd World Congress on Mountain Medicine and High Altitude Physiology, Matsumoto, Japan, Japanese Society of Mountain Medicine. Pages 210–211.
- Oelz O. (1983). High altitude cerebral oedema after positive airway pressure breathing at high altitude (Letter). *Lancet* 2:1148.
- Oelz O., and Largiader J. (1987). Hallucinations and frostbite on Glacier Dome. In: *Hypoxia and Cold*. J.R. Sutton, C.S. Houston, and G. Coates, eds. Praeger, New York; pp. 363–368.
- Pardridge W.M. (2003). Molecular biology of the blood–brain barrier. *Methods Mol. Med.* 89:385–399.
- Provenzale J.M., Wang G.R., Brenner T., Petrella J.R., and Sorensen A.G. (2002). Comparison of permeability in high-grade and low-grade brain tumors using dynamic susceptibility contrast MR imaging. *AJR Am. J. Roentgenol.* 178(3):711–716.
- Raichle M.E., Grubb R.L., and Eichling J.O. (1978). Central neuroendocrine regulation of brain water permeability. *Ciba Found. Symp.* 56:219–235.
- Reeves J.T. (1993). Sympathetics and hypoxia. A brief overview. In: *Hypoxia and Molecular Medicine*. J.R. Sutton, C.S. Houston, and G. Coates, eds. Queen City Press, Burlington, VT; pp. 1–6.
- Roach R.C., and Hackett P.H. (2001). Frontiers of hypoxia research: acute mountain sickness. *J. Exp. Biol.* 204(Pt 18):3161–3170.
- Ross R.T. (1985). The random nature of cerebral mountain sickness. *Lancet* 1:990–991.
- Sanchez del Rio M., and Moskowitz M.A. (1999). High altitude headache. Lessons from headaches at sea level. *Adv. Exp. Med. Biol.* 474:145–153.
- Schoch H.J., Fischer S., and Marti H.H. (2002). Hypoxia-induced vascular endothelial growth factor expression causes vascular leakage in the brain. *Brain* 125(Pt 11):2549–2557.
- Severinghaus J.W. (1995). Hypothesis: angiogenesis cyto-

- kines in high altitude cerebral oedema. *Acta Anaesthesiol. Scand. Suppl.* 107:177–178.
- Singh I., Khanna P.K., Srivastava M.C., Lal M., Roy S.B., and Subramanyam C.S.V. (1969). Acute mountain sickness. *N. Engl. J. Med.* 280:175–184.
- Smith S.M., Zhang Y., Jenkinson M., Chen J., Matthews P.M., Federico A., and De Stefano N. (2002). Accurate, robust, and automated longitudinal and cross-sectional brain change analysis. *Neuroimage* 17(1):479–489.
- Ter Minassian A., Beydon L., Ursino M., Gardette B., Gortan C., and Richalet J.P. (2001). Doppler study of middle cerebral artery blood flow velocity and cerebral autoregulation during a simulated ascent of Mount Everest. *Wilderness Environ. Med.* 12(3):175–183.
- Wiedman M., and Tabin G. (1999). High-altitude retinopathy and altitude illness. *Ophthalmology* 106(10):1924–1927.
- Wieshmann U.C., Clark C.A., Symms M.R., Franconi F., Barker G.J., and Shorvon S.D. (1999). Reduced anisotropy of water diffusion in structural cerebral abnormalities demonstrated with diffusion tensor imaging. *Magn. Reson. Imaging* 17(9):1269–1274.
- Wieshmann U.C., Free S.L., Everitt A.D., Bartlett P.A., Barker G.J., Tofts P.S., Duncan J.S., Shorvon S.D., and Stevens J.M. (1996). Magnetic resonance imaging in epilepsy with a fast FLAIR sequence. *J. Neurol. Neurosurg. Psychiatry* 61(4):357–361.
- Yarnell P.R., Heit J., and Hackett P.H. (2000). High-altitude cerebral edema (HACE): the Denver/Front Range experience. *Semin. Neurol.* 20(2):209–217.
- Zafren K. (1998). Gamow bag for high-altitude cerebral oedema [letter]. *Lancet* 352(9124):325–326.

Address reprint requests to:

Peter H. Hackett
International Society for Mountain Medicine
610 Sabeta Drive
Ridgway, Colorado
81432

E-mail: hackett@hypoxia.net

Received January 20, 2004; accepted in final form March 12, 2004